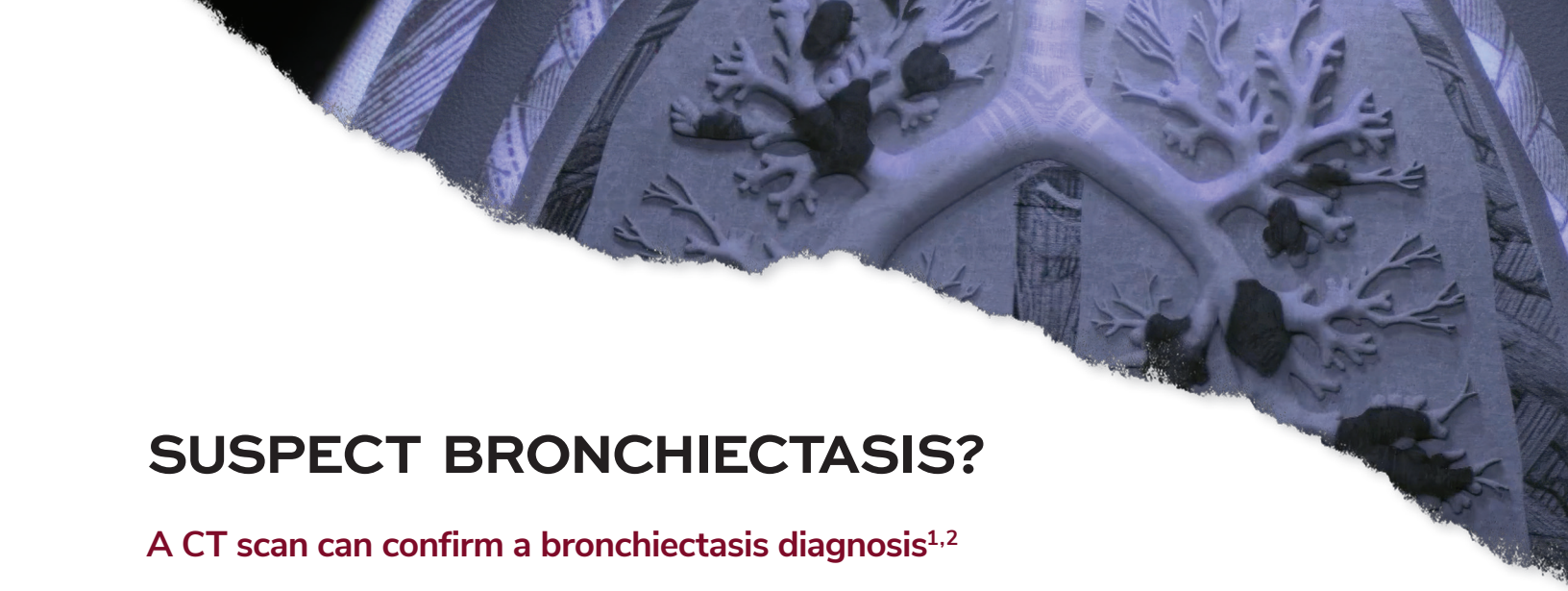

SUSPECT BRONCHIECTASIS?

A CT scan can confirm a bronchiectasis diagnosis[1,2]

Bronchiectasis is a **chronic and progressive inflammatory lung disease** that is characterized by excessive sputum production, a productive cough, and damaging exacerbations.[3-5]

Approximately 500,000 people in the United States are diagnosed with bronchiectasis, while some research points to **over 4 times** that number remaining undiagnosed.[6]

More than 1 in 4 patients with COPD may have bronchiectasis[7,a]

When treating COPD patients with unresolved respiratory symptoms, consider bronchiectasis if you observe[2,8-12]:

- ☐ Large volumes of purulent sputum that persist despite treatment
- ☐ Continuing bacterial infections (especially *Pseudomonas aeruginosa*)
- ☐ Recurrent exacerbations despite standard COPD management
- ☐ COPD diagnosis despite no history of smoking or environmental exposure
- ☐ Symptoms that aren't improving with current treatment regimen

[a]Studies have shown a range of 26% to 69% of people.[7]

CT=computed tomography.

CT imaging is the standard procedure to confirm bronchiectasis[1]

The **2026 GOLD Report for COPD** recommends considering imaging, such as a CT scan, to check for bronchiectasis in patients with COPD who experience exacerbations repeatedly characterized by purulent sputum.[8]

A bronchiectasis diagnosis can help you provide optimized treatments for your patients[11,13-15]



Early diagnosis and adequate management of bronchiectasis may help delay disease progression



In patients with comorbid COPD and bronchiectasis, a different treatment approach may be required to specifically manage the underlying bronchiectasis

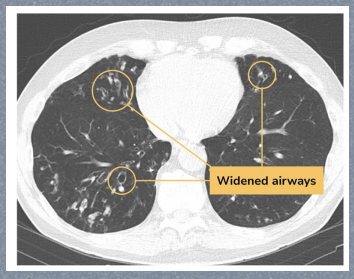

If you suspect bronchiectasis in patients with clinical markers of the disease, include a CT scan in the diagnostic evaluation to confirm or rule it out[1,2]

Learn more about bronchiectasis at SuspectBronchiectasis.com.

References: 1. Chan ED, et al. *Respir Med X*. 2019;1:100006. **2.** Hurst JR, et al. *Eur Respir J*. 2015;45(2):310-313. **3.** Keir HR, Chalmers JD. *Semin Respir Crit Care Med*. 2021;42(4):499-512. **4.** Chalmers JD, et al. *Nat Rev Dis Primers*. 2018;4(1):45. **5.** O'Donnell AE. *N Engl J Med*. 2022;387(6):533-545. **6.** Weycker D, et al. *Chron Respir Dis*. 2017;14(4):377-384. **7.** Ni Y, et al. *Int J Chron Obstruct Pulmon Dis*. 2015;10:1465-1475. **8.** Global Initiative for Chronic Obstructive Lung Disease. Accessed March 19, 2026. https://goldcopd.org/wp-content/uploads/2026/01/GOLD-REPORT-2026-v1.3-8Dec2025_WMV2.pdf **9.** Martinez-Garcia MA, et al. *NPJ Prim Care Respir Med*. 2022;32(1):33. **10.** McShane PJ, et al. *Am J Respir Crit Care Med*. 2013;188(6):647-656. **11.** Alam MA, et al. *Ther Adv Pulm Crit Care Med*. 2024;19:29768675241300808. **12.** Chalmers JD, Sethi S. *NPJ Prim Care Respir Med*. 2017;27(1):18. **13.** Polverino E, et al. *Eur Respir J*. 2017;50(3):1700629. **14.** Chalmers JD, et al. *Eur Respir J*. 2025;66(6):2501126. **15.** Flume PA, et al. *Lancet*. 2018;392(10150):880-890.

insmed

© 2026 Insmed Incorporated. All Rights Reserved. Insmed is a registered trademark of Insmed Incorporated.
All other trademarks are property of their respective owner. NP-BE-US-01095 04/2026